

Comparison between Hepatus[®] and Fibroscan[®] for Evaluating Liver Fibrosis in Chronic Hepatitis B

Jessica Cynthia Febryani, Muhammad Begawan Bestari, Haryono, Dolvy Girawan, Nenny Agustanti, Yudi Wahyudi, Siti Aminah Abdurachman

Division of Gastroentero-hepatology, Department of Internal Medicine, Faculty of Medicine, Universitas Padjadjaran/Hasan Sadikin General Hospital, Bandung

Corresponding author:

M Begawan Bestari. Division of Gastroentero-hepatology, Department of Internal Medicine, Hasan Sadikin General Hospital. Jl. Pasteur No. 38 Bandung Indonesia. Phone: +62-22-2034953/55; Facsimile: +62-22-2032216. E-mail: begawanb@yahoo.com.

ABSTRACT

Background: Among non-invasive strategies available for liver fibrosis assessment, transient elastography is widely used, as it is non-invasive and can be repeated. Hepatus[®] (Mindray, China) is novel instrument that now available in the market with lower price than its precursor, FibroScan[®] (Echosens, Paris). The objective of this study is to identify the comparison between Hepatus[®] and FibroScan[®] in measuring liver stiffness for evaluation of liver fibrosis in chronic hepatitis B (CHB).

Method: In this cross sectional study, CHB patients in single center were recruited consecutively in October-December 2021. The patients were examined for liver stiffness measurement (LSM) with two transient elastography instruments in one visit; Hepatus[®] (Mindray, China) and FibroScan[®] (Echosens, Paris). Both measurements were done by the same operator.

Results: A total of 68 CHB patients were enrolled in this study. Median score of LSM by Hepatus[®] and FibroScan[®] were 7.6 (5.92-11.88) and 7.35 (5.63-11.80), respectively. Spearman rank analysis showed a significant correlation between the results of the two instruments ($r = 0.8, p < 0.05$). The number of patients with significant fibrosis (≥ 8 kPa) identified by Hepatus[®] and FibroScan[®] were 28 (41%) and 29 (43%), respectively. McNemar test yielded no significant difference of the results ($p = 1.000$), and Cohen's kappa measure of agreement showed moderate agreement ($\kappa = 0.789$ and $p < 0.005$).

Conclusion: Hepatus[®] identified similar number of significant fibrosis patients with FibroScan[®], and significant correlation presented between the results of LSM. Hepatus[®] has a potential as an alternative for measuring liver stiffness with a more economic price.

Keywords: Hepatus[®], FibroScan[®], transient elastography, liver fibrosis, chronic hepatitis B (CHB)

ABSTRAK

Latar belakang: Elastografi hati merupakan salah satu teknik pemeriksaan fibrosis hati yang bersifat non invasif dan dapat diulang. Hepatus[®] (Mindray, China) adalah salah satu alat yang kini tersedia di pasar dengan harga yang lebih murah dibandingkan pendahulunya, FibroScan[®] (Echosens, Paris). Tujuan penelitian ini adalah melakukan perbandingan antara Hepatus[®] dan FibroScan[®] dalam mengukur kekakuan hati sebagai evaluasi fibrosis hati pada pasien Hepatitis B kronis.

Metode: Pasien dengan Hepatitis B kronis pada sebuah institusi kesehatan direkrut secara konsekutif pada Oktober-Desember 2021 secara cross sectional. Pemeriksaan elastografi hati dilakukan dengan dua alat, yaitu Hepatus® dan FibroScan® dalam satu kunjungan oleh operator yang sama.

Hasil: Pasien Hepatitis B Kronis sejumlah 86 direkrut dalam studi ini. Nilai median kekakuan hati pada masing-masing alat yaitu 7.6 (5.92-11.88) pada Hepatus® dan 7.35 (5.63-11.80) pada FibroScan®. Analisis korelasi menggunakan Spearman menunjukkan korelasi yang signifikan ($r = 0.8$, $p < 0.05$), dan jumlah pasien dengan fibrosis signifikan yang diidentifikasi oleh Hepatus® dan FibroScan® adalah 28 (41%) dan 29 (43%). Hasil uji Mc Nemar menunjukkan tidak terdapat perbedaan yang bermakna antara hasil dari dua alat tersebut ($p = 1.000$), sedangkan pengukuran dengan Cohen's Kappa menunjukkan konsistensi pengukuran moderat antara Hepatus® dan FibroScan®.

Simpulan: Hepatus® mengidentifikasi jumlah pasien dengan fibrosis signifikan dengan hasil yang serupa dengan hasil FibroScan® dan terdapat korelasi signifikan antara hasil pengukuran kekakuan hati kedua alat tersebut. Hepatus® memiliki potensi sebagai alat alternatif untuk pengukuran kekakuan hati dengan harga yang lebih ekonomis.

Kata kunci: Hepatus®, FibroScan®, elastografi hati, fibrosis hati, hepatitis B kronis

INTRODUCTION

Chronic hepatitis B (CHB) is a public health burden worldwide, and Indonesia is no exception. Prevalence of CHB in Indonesia is 7.1% in 2013 National Health Survey, equivalent with 18 million people infected.¹ CHB also contributes a high number of morbidity and mortality, mainly due to the progression of the disease.² CHB remained the leading cause of liver cirrhosis and hepatocellular carcinoma worldwide, thus evaluating the progression of the disease, namely fibrosis staging, is of paramount importance.³ In addition, liver fibrosis assessment is essential in assisting diagnosis and antiviral treatment decision in CHB.^{4,5}

Liver biopsy, as the gold standard in fibrosis assessment, is an invasive and expensive method.⁶ These disadvantages make liver biopsy an unsuitable method for repeated assay. Many non-invasive strategies have been developed in the last decades as surrogates to aid fibrosis assessment in CHB. There are indirect and direct markers for fibrosis, ultrasound-based transient elastography and magnetic resonance elastography.⁷ Among non-invasive strategies available for liver fibrosis assessment, transient elastography is widely used, as it is non-invasive, practical, rapid and reproducible.^{8,9}

First introduced in 2003, FibroScan® (Echosens, Paris) was the first ultrasound-based elastography introduced and well established in many researches.¹⁰ FibroScan® is a useful instruments in various hepatic diseases; Hepatitis B, Hepatitis C and non-alcoholic fatty liver disease (NAFLD).¹¹ Hepatus® (Mindray, China), on the other hand, is one novel instrument for measuring liver stiffness that is now available in the

market with lower price than its precursor, FibroScan®. Hepatus® was declared by food and drug administration (FDA) in July 2020 as substantially equivalent with respect to safety and efficacy to commercially available device.¹² This study aims to figure the comparison between the two instruments in measuring liver stiffness as non-invasive strategies for evaluation of liver fibrosis in CHB patients clinically.

METHOD

In this cross sectional study, CHB patients in gastroenterology and hepatology clinics Hasan Sadikin Hospital were recruited consecutively in October-December 2021. Patients included in this study were aged 18 and above with diagnosis of chronic hepatitis B from history taking, physical examination, and laboratory value, including serum HBV DNA > 20,000 IU/mL on positive HbeAg or >2,000 IU/mL on negative HbeAg and persistent or intermittent increase of alanine aminotransferase (ALT). Exclusion criteria in this study were acute hepatitis B, presence of ascites, hepatitis C, autoimmune hepatitis, coinfection with hepatitis C or human immunodeficiency virus (HIV), history of alcohol consumption, and pregnancy. All the patients had received explanations and signed informed consent form prior to examination. This study had been approved by Health Research Ethics Committee Padjadjaran University/Hasan Sadikin Hospital.

The patients were examined for liver stiffness measurement (LSM) with two instruments for transient elastography in one visit. The first instrument was Hepatus® (Mindray, China) and the second one was

FibroScan® (Echosens, Paris). Both measurements were done by the same operator. Successful measurement must fulfill (1) 10 valid shots; (2) Success rate (ratio of valid shots to total number of shots) above 60% and (3) Ratio of Interquartile Range to Median LSM value (IQR/M) ≤ 0.3 (30%).⁸ Blood tests were also drawn on the same day for routine tests.

Data were collected and analyzed using SPSS version 26. Normally distributed data were displayed as mean and standard deviation, while median and interquartile range value were used for data with abnormal distribution. Categorical data were represented as percentages. Wilcoxon test was used to determine the difference of paired test between FibroScan® and Hepatus®, while Spearman correlation coefficients were obtained to determine correlation of the results. McNemar test was applied to determine the difference between paired categorical data, and Cohen’s kappa measure of agreement was used to find the agreement between two instruments. Significant value was determined by $p < 0.05$.

RESULTS

A total of 68 CHB outpatients were enrolled in this study (Table 1). The patients’ gender distribution was similar between male and female, with average age of 44 years old. There were 21 (31%) treatment naïve patients, and 47 (69%) patients already received antiviral treatment. Routine laboratory test revealed no exacerbation of CHB among patients.

Results of LSM by both instruments were displayed in Table 2. Median score of LSM by Hepatus® and FibroScan® were 7.6 (5.92-11.88) and 7.35 (5.63-11.80), respectively. Wilcoxon test revealed no significant difference between the results of the two instruments ($p = 0.110$). Spearman rank analysis for correlation between LSM of the two instruments showed a significant correlation, with high ratio of 0.8 ($p < 0.05$). Agreement between two instruments was displayed in Bland-Altman plot (Figure 1).

The number of patients with significant fibrosis (LSM ≥ 8 kPa) identified by Hepatus® and FibroScan® were 28 (41%) and 29 (43%), respectively. McNemar analysis gave no significant result of difference between the two instruments in differentiating significant and non significant fibrosis as shown in Table 3. This was further supported by Cohen’s kappa measure of agreement with result $\kappa = 0.789$ and $p < 0.005$.

Table 1. Characteristics data of participants

Variable	Total (n = 68)
Age (years), mean \pm SD	44 \pm 13
Sex, n (%)	
Male	36 (52.9)
Female	32 (47.1)
BMI (kg/m ²), mean \pm SD	22.7 \pm 2.8
HBeAg	
Positive	12 (18%)
Negative	45 (82%)
Treatment status	
Naïve	21(31%)
Experienced	47 (69%)
Routine tests	
Platelets, median (IQR)	223500 (190000 – 286250)
PT, median (IQR)	13.95 (13.40 – 14.58)
INR, median (IQR)	0.97 (0.92 – 1.02)
AST, median (IQR)	26 (22 – 34.5)
ALT, median (IQR)	38.5 (27 – 50.75)
Bilirubin Total, median (IQR)	0.577 (0.3975 – 0.808)
Albumin, median (IQR)	4.06 (3.80 – 4.25)

BMI: body mass index, HBeAg: hepatitis B early antigen, PT: prothrombin time
INR: International normalized ratio, AST: aspartate aminotransferase,
ALT: alanine aminotransferase

Table 2. Correlation of fibrosis results of Hepatus® and FibroScan®

Variable	Total (n = 68)		p
	Hepatus®	FibroScan®	
LSM	7.6 (5.92-11.88)	7.35 (5.63-11.80)	< 0.005

Table 3. Comparison of fibrosis results of Hepatus® and FibroScan®

Variable	FibroScan®		p
	Not significant	Significant	
Hepatus®			
Not significant	36 (52.9%)	4 (5.9%)	1.000
Significant	3 (4.4%)	25 (36.4%)	

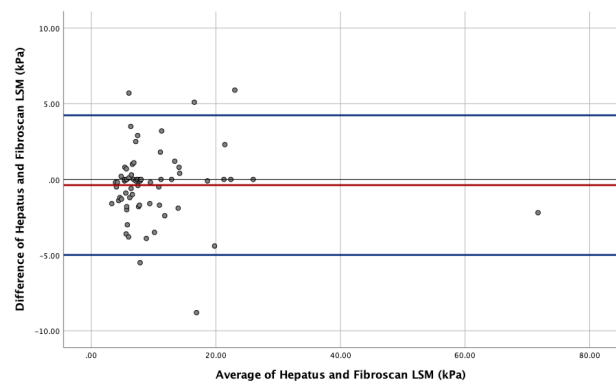


Figure 1. Bland Altman plot with lines of agreement

DISCUSSION

Transient elastography (TE) is an imaging technique using one dimensional ultrasound that measure velocity of a low-frequency (50 Hz) elastic shear wave propagating through the liver.¹³ The stiffer the liver, velocity of the wave will increase, hence differentiating the elasticity of the liver observed. The degree of the stiffness reflects the degree of liver fibrosis, and this value is expressed in kiloPascals (kPa)

ranging from 4.0 to 75 kPa.¹⁴ Significant fibrosis in CHB is defined as equal and greater than 8.0 kPa in liver stiffness measurement (LSM).¹⁵

Since TE first introduced in Europe, the breakthrough fibrosis assessment has been analyzed worldwide in various diseases. Its capability in HBV patients made FibroScan® one of the suggested measurements for liver stiffness and grading liver fibrosis by WHO, AASLD and EASL.^{2,4,16} TE is also a reliable tool for predicting prognosis in CHB and for following up in patients receiving antiviral treatment to assess improvement in liver fibrosis over time.¹⁷

This study highlighted the use of novel device for LSM, Hepatus®, which shown to yield similar results with its widely used precursor, FibroScan®. Comparing the LSM results between the two instruments, statistic analysis proves the value to be not statistically different, meaning similar results were yielded. Correlation between the two measurements also shown to be highly correlated with significant result ($r = 0.8$, $p < 0.05$).

FibroScan® has good performance in differentiating significant fibrosis and cirrhosis in CHB with AUROC 0.81-0.95 and 0.8–0.98, for cut off of 6.3–7.9 and 9.0–13.8 kPa respectively.¹⁸ Among 68 CHB patients, Hepatus® identified similar number of significant fibrosis patients with FibroScan®, that was 28 (41%) patients by Hepatus® and 29 (43%) patients by FibroScan® (Table 3). These results were regarded as not significantly different after statistically analyzed. Analysis for agreement between these two instruments also showed significant result with moderate strength of agreement ($\kappa = 0.789$, $p < 0.005$), applying cut off of ≥ 8 kPa for significant fibrosis in both instruments. This prove Hepatus® capacity to differentiate significant fibrosis with similar results as FibroScan®, which was crucial regarding antiviral treatment decision. Antiviral treatment in CHB not only could suppressed viral load and aid in fibrosis regression, but also beneficial in reversal of cirrhosis.¹⁹

There is no study yet to compare Hepatus® and FibroScan® in measuring liver stiffness for CHB patients. Study by Ren et al in 2020 was aimed in comparing both instruments for steatosis measurement in CHB patients. The results of the study demonstrated good capacity of Hepatus® in measuring steatosis. Hepatus® was not inferior to FibroScan®, even better in determining steatosis level using the suitable cut off.²⁰

Current LSM using TE has several limitations. One of shortcomings addressed in FibroScan® is choosing the right probe for different characteristics of patient, for example BMI and skin to capsule

distance (SCD).^{21,22} M probe FibroScan® is only able to measure velocity of returning shear at a depth of 25-65 mm, while XL probe measure at a deeper level of 35-75mm.²³ This might be overcome by Hepatus® with its universal probe, yet further study might be beneficial to confirm this. Hepatus® also enforce real time ultrasound imaging, introducing the new era of visual transient elastography (ViTE), assisting a more accurate examination and reducing the operation difficulty. Other issue that might be able to be tackled by Hepatus®, was economic burden in health sectors, as it was available in more economic price at the market.

The liabilities of this study were the small number of subjects, single center nature of the study and the overlook of liver biopsy as standard for liver fibrosis assessment. Further study with large scale of subjects and the employment of liver biopsy might be carried out to validate and further confirming the prospective of Hepatus®.

CONCLUSION

Hepatus® identified similar number of significant fibrosis patients with FibroScan®, and the results of liver stiffness measurement between the two instruments correlated significantly with no significant difference. The availability of Hepatus® in the market might bring beneficial value, especially in limited resources area. In conclusion, Hepatus® has a potential as an alternative tool for measuring liver stiffness with a more economic price.

REFERENCES

1. Badan Penelitian dan Pengembangan Kesehatan Kementerian RI. Riset Kesehatan Dasar (Riskesdas) 2013 [serial online] [cited 20 Februari 2022]. Available from <https://pusdatin.kemkes.go.id/resources/download/general/Hasil%20Riskesdas%202013.pdf>
2. European Association for the Study of the Liver. Electronic address: easloffice@easloffice.eu; European Association for the Study of the Liver. EASL 2017 Clinical Practice Guidelines on the management of hepatitis B virus infection. *J Hepatol* 2017;67:370-98.
3. Galle PR, Forner A, Llovet JM. EASL Clinical practice guidelines: management of hepatocellular carcinoma. *J Hepatol* 2018;69:182-236.
4. Terrault NA, Lok ASF, McMahon BJ, Chang KM, Hwang JP, Jonas MM, et al. Update on prevention, diagnosis, and treatment of chronic hepatitis B: AASLD 2018 hepatitis B guidance. *Hepatology* 2018;67:1560-99.
5. Yim HJ, Kim JH, Park JY, Yoon EL, Park H, Kwon JH, et al. Comparison of clinical practice guidelines for the management of chronic hepatitis b: When to start, when to change, and when to stop. *Clin Mol Hepatol* 2020;26:411-29.

6. Zeng DW, Dong J, Liu YR, Jiang JJ, Zhu YY. Non-invasive models for assessment of liver fibrosis in patients with chronic hepatitis B virus infection. *World J Gastroenterol* 2016;22:6663-72.
7. Stasi C, Milani S. Non-invasive assessment of liver fibrosis: between prediction/prevention of outcomes and cost-effectiveness. *World J Gastroenterol* 2016;22:1711-20.
8. Castera L, Yuen Chan HL, Arrese M. EASL-ALEH clinical practice guidelines: non-invasive tests for evaluation of liver disease severity and prognosis. *J Hepatol* 2015;63:237-64.
9. Gheorghe G, Bungău S, Ceobanu G, Illie M, Bacalbasa N, Bratu OG, et al. The non-invasive assessment of hepatic fibrosis. *J Formos Med Assoc* 2021;120:794-803.
10. Chin JL, Pavlides M, Moolla A, Ryan JD. Non-invasive markers of liver fibrosis: adjuncts or alternatives to liver biopsy? *Front Pharmacol* 2016;7:159.
11. Li Q, Huang C, Xu W, Hu Q, Chen L, Pan. JJ. Accuracy of FibroScan in analysis of liver fibrosis in patients with concomitant chronic hepatitis B and non-alcoholic fatty liver disease. *Medicine (United States)* 2020;99:e20616.
12. FDA. Hepatus 7/Hepatus 6/Hepatus 5/Hepatus 7S/Hepatus 6S/Hepatus 5S/Hepatus 7T/Hepatus 6T/Hepatus 5T/Fibrous 7/Fibrous. [cited 20 February 2022]. Available from :<https://www.accessdata.fda.gov/scripts/cdrh/cfdocs/cfRL/rl.cfm?lid=710282&lpd=ITX>
13. Lurie Y, Webb M, Cytter-Kuint R, Shteingart S, Lederkremer GZ. Non-invasive diagnosis of liver fibrosis and cirrhosis. *World J Gastroenterol* 2015;2141:11567-83.
14. Parikh P, Ryan JD, Tsochatzis EA. Fibrosis assessment in patients with chronic hepatitis B virus (HBV) infection. *Ann Transl Med* 2017;5:40.
15. Chon YE, Choi EH, Song KJ, Park JY, Kim DY, Han KH, et al. Performance of transient elastography for the staging of liver fibrosis in patients with chronic hepatitis B: a meta-analysis. *PLoS ONE* 2012;7:e44930.
16. WHO. Guidelines for the prevention, care and treatment of persons with chronic hepatitis B infection. Geneva: World Health Organization; March 2015.
17. Yu JH, Lee J il. Current role of transient elastography in the management of chronic hepatitis B patients. *Ultrasonography* 2017;36:86-94.
18. Sarin SK, Kumar M, Lau GK, Abbas Z, Chan HLY, Chen CJ, et al. Asian-pacific clinical practice guidelines on the management of hepatitis B: a 2015 update. *Hepatol Int* 2016;10:1-98.
19. Patel K, Sebastiani G. Limitations of non-invasive tests for assessment of liver fibrosis 2020;2:100067.
20. Ren X, Xia S, Zhang L, Li R, Zhou W, Ji R, et al. Analysis of liver steatosis analysis and controlled attenuation parameter for grading liver steatosis in patients with chronic hepatitis B. *Quant Imaging Med Surg* 2021;11:571-8.
21. Berger A, Shili S, Zuberbuhler F, Hiriart JB, Lannes A, Chermak F, et al. Liver stiffness measurement with fibroscan: use the right probe in the right conditions. *Clin Translational Gastroenterol* 2019;10:e00023.
22. Myers RP, Pomier-Layrargues G, Kirsch R, Myers RP, Pollett A, Beaton M, et al. Discordance in fibrosis staging between liver biopsy and transient elastography using the FibroScan XL probe. *J Hepatol* 2012;56:564-70.
23. Chang PE, Goh GB, Ngu JH, Tan HK, Tan CK. Clinical applications, limitations and future role of transient elastography in the management of liver disease. *World J Gastrointest Pharmacol Ther* 2016;7:91-106.