

## Adult Ileocecal Intussusception: A Case Report and Review

Randy Adiwinata\*, Sheila Adiwinata\*\*, Emerson Patulahon Simatupang\*\*\*,  
Willy Brodus Uwan\*\*\*\*, Marcellus Simadibrata\*\*\*\*\*

\*Landak Public Hospital, Ngabang, West Kalimantan

\*\*Faculty of Medicine, Catholic University of Atma Jaya, Jakarta

\*\*\*Department of Surgery, Landak Public Hospital, Ngabang, West Kalimantan

\*\*\*\*Endoscopy Unit, Santo Antonius Hospital, Pontianak, West Kalimantan

\*\*\*\*\*Division of Gastroenterology, Department of Internal Medicine, Faculty of Medicine  
University of Indonesia/Dr. Cipto Mangunkusumo General National Hospital, Jakarta

### Correspondence Author:

Randy Adiwinata, Landak Public Hospital. Jl. Raya Ngabang Sanggau No 109 Ngabang Indonesia.  
Phone/facsimile: +62-563-2022845. Email: randyadiwinata@yahoo.com

### ABSTRACT

*Intussusception is a rare cause of bowel obstruction in adult patients, it represents for five percent of all age intussusception. Several different aspects were found between adult and pediatric intussusception. We report a case of 39-year-old male with bowel obstruction due to ileocecal intussusception, which firstly diagnosed as acute appendicitis. Unlike pediatric intussusception which usually manifest as classical triad signs, unspecific symptoms of adult intussusception may become diagnostic challenge. Imaging modalities such as plain abdominal radiograph and ultrasonography may aid the preoperative diagnosis in the rural hospital setting. Prompt management which involved surgical approach is warranted to prevent further complications.*

**Keywords:** *adult intussusception, diagnosis, management, bowel obstruction, ileocecal*

### ABSTRAK

*Intususepsi merupakan kasus langka obstruksi usus pada orang dewasa, diperkirakan hanya menyumbang sekitar 5% dari keseluruhan usia penderita intususepsi. Terdapat beberapa perbedaan karakteristik antara intususepsi pada orang dewasa dengan anak-anak. Kami melaporkan sebuah kasus seorang pria berusia 39 tahun yang mengalami obstruksi usus diakibatkan oleh intususepsi, yang semula terdiagnosis sebagai apendisitis akut. Tidak seperti intususepsi pada anak yang selalu menunjukkan 3 tanda klasik, penegakkan diagnosis intususepsi pada orang dewasa yang menunjukkan gejala tidak khas cukup menyulitkan. Pencitraan seperti foto polos abdomen dan ultrasonografi dapat membantu penegakkan diagnosis preoperasi pada rumah sakit di pedalaman. Tindakan seperti operasi diperlukan untuk mencegah komplikasi lebih lanjut.*

**Kata kunci:** *adult intussusception, diagnosis, management, bowel obstruction, ileocecal*

### INTRODUCTION

Intussusception is an uncommon cause of bowel obstruction in adult compared to children group.

Intussusception defined as a segment of bowel (intussusceptum) may along with the mesentery telescoping into the adjacent distal bowel lumen

(intussusciens).<sup>1</sup> Adult intussusception is estimated account for 5 percent of all age intussusception and contribute to 1-5% of intestinal obstruction.<sup>2</sup>

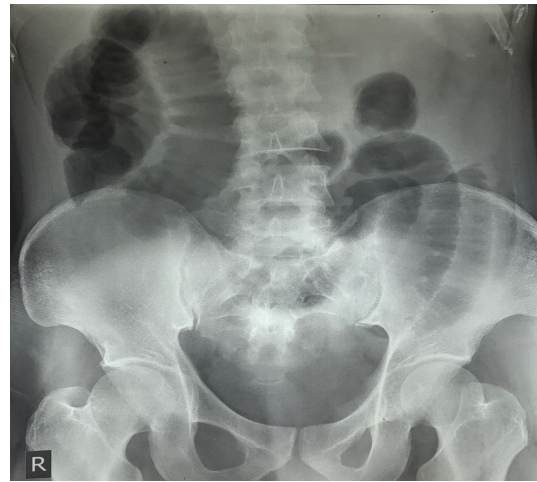
Intussusception in adult rarely presented as the classical triad signs as in the pediatrics group, and also more associated with pathological conditions which served as the lead point of intussusception.<sup>3,4</sup> Classification of adult intussusception was made according to the lead point anatomical location which defined as ileocolic, ileocecal, colocolic, and enterocolic intussusception.<sup>1</sup>

Due to the rare nature of intussusception as the cause of bowel obstruction in adult, diagnosis can be challenging and delayed. The use of plain abdominal radiograph and ultrasonography may aid the preoperative diagnosis of intussusception, especially in rural setting where Computed tomography scan (CT-scan) is unavailable. Prompt diagnosis and management are warranted for better outcome.<sup>3</sup> Here, we present a 39-year-old male presented in rural hospital with bowel obstruction due to ileocecal intussusception, which previously diagnosed as acute appendicitis.

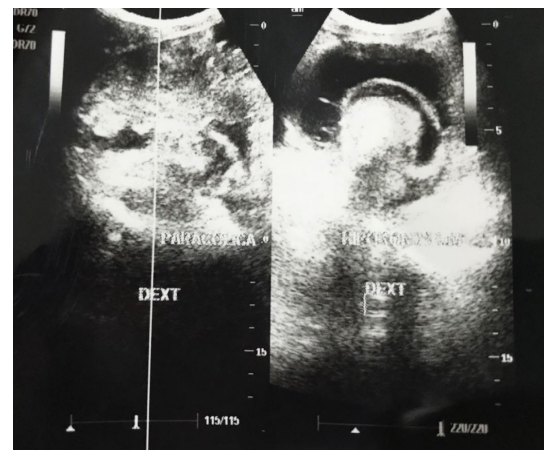## CASE ILLUSTRATION

A 39-year-old male presented to our emergency department (ED) with sudden severe right lower quadrant pain since 12 hours before admission. The pain was rated as eight out of ten, according to Visual Analog Scale. He also complained abdominal distention and vomiting every time he ate; he denied any fever, bowel movements and flatus since the abdominal pain occurred. His past medical history was unremarkable.

On physical examination, he appeared moderately ill with blood pressure of 150/90 mmHg, heart rate of 100, Respiratory rate of 20, and temperature of 36.4°C. Abdominal examination revealed moderate distention and tenderness on right lower quadrant without muscle guarding or rigidity, hyperactive and high pitched bowel sounds, also hypertympanic percussion. The patient first was assessed as acute appendicitis and possible having bowel obstruction. The initial laboratory examination revealed anemia (hemoglobin 10.4 gr/dL), leukocytosis (15,000 cells/mm<sup>3</sup>), and normal platelet count (242,000 cells/mm<sup>3</sup>). Plain abdominal radiograph showed small bowel obstruction (Figure 1) and ultrasonography (USG) showed dilated bowel and target lesion in the transversal view (Figure 2), therefore concluded as bowel obstruction due to ileocecal intussusception. CT-scan was not available in our hospital.



**Figure 1. Plain abdominal radiograph showed small bowel obstruction**



**Figure 2. USG showed target lesion in transversal view**

Emergency laparotomy was performed. Intraoperative findings showed ileocecal intussusception, and due to ischemic colon caused by intussusception, right hemicolectomy and anastomosis to transverse colon were performed. Specimen was not examined for histopathology due to the limited setting. No visible lead point was identified during the operation. The post operative course was unremarkable. Return of normal bowel function was found on his second postoperative day. Patient was self discharged five days after the operation.

## DISCUSSION

Intussusception is defined as the telescoping of proximal segment of the gastrointestinal tract into the lumen of the adjacent distal segment.<sup>4</sup> Adult intussusception is distinct in various aspects from pediatric intussusception (Table 1). First of all, adult intussusception is considered as rare condition that constitutes of 5% of all intussusception cases and

contribute 1-5% as the cause of intestinal obstruction.<sup>2</sup> Almost 90% of adult intussusception cases were caused due to pathological condition which served as the lead point. Several case reports showed variable pathological causes of secondary adult intussusception ranging from benign and malignant lesions and can be due to intraluminal or extraluminal lesions such as lipoma, gastrointestinal stromal tumor, ovarian cancer, polyp, lymphoma, hamartoma, post-operative adhesion, Meckel's diverticulum, metastases, and inflammatory lesions.<sup>5-9</sup> In majority, lead points that arise from small intestine are tend to be benign, while lesions in large colon usually malignant.<sup>9</sup> In contrast, almost 90% of pediatric intussusception is idiopathic.<sup>10</sup>

The classical triad of acute pediatric intussusception presentation consists of palpable tender abdominal mass, colicky abdominal pain, and red-currant jelly stool. However, this classic triad is rarely presented in adults.<sup>3</sup> The clinical manifestations of adult intussusception are unspecific and variable. As in our patient, the patient showed right lower quadrant pain, recurrent vomiting, and absence of flatus and passing stool; due to the rare occurrence of adult intussusception, we suspect of acute appendicitis and bowel obstruction at first. Other non-specific manifestations of adult intussusception are abdominal distention, constipation, fever, hematochezia, cramping and nausea.<sup>3,4,11</sup> Symptoms can be manifested as acute or chronic lasting up to months-year.<sup>3,11</sup>

According to the location that the intussusceptions may occurred, intussusceptions can be categorized into four categories: The most common type is: (1) Enteric intussusception which confined to small bowel and may be found in 43% of patients; (2) Colocolic type which occurred in 22% of cases and only involving the large bowel; (3) Ileocecal type which occurred when the ileocecal valve act as the leading point of intussusception and found in 21% of cases; (4) Ileocolic type that occurred in 14% cases and defined as prolapse of the ileum through ileocecal valve into the colon.<sup>3,4,9</sup>

Due to the unspecific clinical manifestations of adult intussusception, imaging modalities played significant role in aiding the preoperative diagnosis of adult intussusception.<sup>4</sup> In the setting of limited resources healthcare settings, plain abdominal films

and ultrasound may become useful tools for diagnosis of intussusception and excluding other etiology for acute abdominal pain. Plain abdominal radiography can be used as first line to identify bowel obstruction or perforation and may provide information regarding the obstruction site, especially when the CT-scan is not available. However, it has low sensitivity and specificity for intussusception diagnosis.<sup>4,12</sup> Barium enema examination may give additional information and provide characteristic finding in certain type of intussusception.<sup>4</sup>

Abdominal USG is useful in aiding the diagnosis of intussusception especially in limited setting because of its cost-effectiveness and also absence of radiation. As in our case, intussusception was diagnosed preoperatively because the USG examination showed classic sign of intussusception which is "target" sign in transversal view and "hay-fork" sign in the longitudinal view.<sup>4</sup>

Beside of the intussusception diagnosis, CT-scan (especially with contrast) may provide more information regarding the site and cause of obstruction, possible lead point, surrounding viscera, vasculatures, and strangulation possibility.<sup>1</sup> Classic finding for intussusception are target lesion or sausage shaped mass.<sup>13</sup> CT-scan examination also not impaired by the obesity figure of patient or bowel gas as it may impair the USG examination interpretation result.<sup>3</sup>

Nowadays, the use of flexible endoscopy may aid the diagnosis of intussusception, especially in the setting of patient with subacute or chronic large bowel obstruction. Endoscopy may give information regarding the exact level of intussusception and the pathologic lesions that determined as lead point.<sup>4</sup> Kim et al reported successful intussusception reduction by air infusion through endoscopy in patients with intussusception due to intestinal tuberculosis; therefore, endoscopy may become possible alternative therapeutic modality.<sup>14</sup>

In adult intussusception cases, surgical resection of involved bowel segments is the recommended approach. This recommendation was made due to the nature of etiology of adult intussusception case, which are commonly secondary to pathological lesions.<sup>2</sup> In contrast with pediatric intussusception, which mostly are idiopathic therefore simple reduction

**Table 1. Differences between adult and pediatric intussusception<sup>2,4</sup>**

	<b>Adult</b>	<b>Pediatric</b>
Incidence	Rare (approximately 5% of all intussusception cases)	More common
Etiology and mechanism	Mostly secondary due to pathological lesion	Mostly primary and benign
Clinical manifestation	Variably	Classical triad of palpable tender abdominal mass, colicky abdominal pain, and red-currant jelly stool
Management	Usually pneumatic or hydrostatic reduction is sufficient	Surgical management is recommended

either by pneumatic or hydrostatic may be sufficient.<sup>4</sup> The decision for primary reduction before resection remains controversial. The possible cause of adult intussusception is malignancy, therefore some authors argued that reductions may accelerated the intraluminal seeding and venous dissemination of malignant cells, or increased risk for perforation.<sup>9</sup>

Intussusception in adult population is rare. Adult intussusception is different with pediatric intussusception in many aspects. Unspecific clinical presentation in adult intussusception may become diagnostic challenge. Imaging modalities are usually needed to establish preoperative diagnosis. Surgical approach is recommended in adult intussusception due to the common secondary pathological lesion finding as the intussusception cause.

## REFERENCES

1. Shenoy S. Adult intussusception: a case series and review. *World J Gastrointest Endosc* 2017;9:220-7.
2. Ibrahim D, Patel NP, Gupta M, Fox JC, Lotfipour S. Ileocecal intussusception in the adult population: case series of two patients. *West J Emerg Med* 2010;11:197-200.
3. McKay R. Ileocecal intussusception in an adult: the Laparoscopic Approach. *JLS* 2006;10:250-3.
4. Marinis A, Yiallourou A, Samanides L, Dafnios N, Anastasopoulos G, Vassiliou I, et al. Intussusception of the bowel in adults: a review. *World J Gastroenterol* 2009;15:407-11.
5. Lianos G, Xeropotamos N, Bali C, Baltogiannis G, Ignatiadou E. Adult bowel intussusception: presentation, location, etiology, diagnosis and treatment. *G Chir* 2013;34:280-3.
6. Ssentongo P, Egan M, Arkorful TE, Dorvlo T, Scott O, Oh JS, et al. Adult intussusception due to gastrointestinal stromal tumor: a rare case report, comprehensive literature review and diagnostic challenges in low-resource countries. *Case Rep Surg* 2018;2018:1395230.
7. Sullivan MW, Modesitt SC. Intussusception as a rare cause of bowel obstruction in a woman with recurrent ovarian cancer. *Gynecol Oncol Rep* 2018;26:4-6.
8. Bilgin M, Toprak H, Ahmad IC, Yardimci E, Kocakoc E. Ileocecal intussusception due to a lipoma in an adult. *Case Reports in Surgery* 2012;2012:1-3.
9. Gupta RK, Agrawal CS, Yadav R, Bajracharya A, Sah PL. Intussusception in adults: institutional review. *Int J Sug* 2011;9:91-5.
10. Yalamarthi S, Smith RC. Adult intussusception: case reports and review of literature. *Postgrad Med J* 2005;81:174-7.
11. Yakan S, Caliskan C, Makay O, Denecli AG, Korkut MA. Intussusception in adults: clinical characteristics, diagnosis and operative strategies. *World J Gastroenterol* 2009;15:1985-9.
12. Paulson EK, Thompson WM. Review of small-bowel obstruction: the diagnosis and when to worry. *Radiology* 2015;275:332-40.
13. Kim YH, Blake MA, Harisinghani MG, Arroyo KA, Hahn PF, Pitman MB, et al. Adult intussusception: CT appearances and identification of a causative lead point. *Radiographics* 2006;26:733-43.
14. Kim D, Jung H, Kim M, Lee J, Kim S, Kang D, et al. Endoscopic treatment of intussusception due to intestinal tuberculosis. *Clin Endosc* 2017;50:206-8.