

## Imaging Modalities Role in Recurrent Acute Pancreatitis Diagnosis

Andreas Pekey\*, Rio Zakaria\*, Leonard Nianggolan\*\*, Ari Fahrial Syam\*\*\*, Dadang Makmun\*\*\*

\* Department of Internal Medicine, Faculty of Medicine, University of Indonesia/Dr. Cipto Mangunkusmo General National Hospital, Jakarta

\*\* Division of Tropical and Infectious Disease, Department of Internal Medicine, Faculty of Medicine, University of Indonesia/Dr. Cipto Mangunkusmo General National Hospital, Jakarta

\*\*\* Division of Gastroenterology, Department of Internal Medicine, Faculty of Medicine, University of Indonesia/Dr. Cipto Mangunkusmo General National Hospital, Jakarta

### ABSTRACT

Recurrent acute pancreatitis (RAP) is a potentially life-threatening pancreatic disorder. It requires a combination of medical and interventional skills to diagnose, determine the etiology, and treat the condition. Recurrences occur in 25-30% of all acute pancreatitis cases. The most common cause of RAP is gallstone (microlithiasis). Imaging modalities become an important aspect to evaluate multiple microlithiasis. In this case, we report a 52 years old overweight female with RAP and fatty liver of unknown etiology. We suspected gallstone as the cause of RAP. Physical examination considered normal. Ultrasound and abdominal CT scan was performed in which fatty liver were founded. Since the gallstone is not clearly found with radiologic imaging, we decide to undergo Endoscopic Retrograde Cholangiopancreatography (ERCP) procedure to evaluate a possibility of microlithiasis. ERCP result showed a multiple microlithiasis, thus we evacuate the stones. Clinical outcome post ERCP and evacuation procedure was good. We concluded that the best imaging modalities to evaluate microlithiasis in RAP with normal ultrasound and abdominal CT scan is ERCP.

**Keywords:** recurrent acute pancreatitis (RAP), microlithiasis, endoscopic retrograde cholangiopancreatography (ERCP).

### ABSTRAK

Pankreatitis akut berulang merupakan kondisi yang berpotensi mengancam jiwa sehingga membutuhkan kombinasi pengetahuan klinis dan ketrampilan dalam mendiagnosis, mengetahui penyebabnya, serta mengobatinya. Pankreatitis akut berulang terjadi pada 25-30% kasus pankreatitis akut. Penyebab tersering dari pankreatitis akut berulang adalah batu empedu. Pemeriksaan radiografi menjadi penting dalam mengevaluasi batu empedu atau mikrolitiasis multipel. Pada kasus ini, kami melaporkan seorang wanita overweight berusia 52 tahun dengan pankreatitis akut berulang dan perlemakan hati (fatty liver) yang tidak diketahui penyebabnya. Batu empedu dicurigai sebagai penyebab dari pankreatitis akut berulang. Pemeriksaan fisik dalam batas normal. Pemeriksaan ultrasonografi dan computerized tomography (CT) scan abdomen hanya menunjukkan adanya perlemakan hati. Karena pemeriksaan dengan kedua modalitas tersebut belum berhasil menemukan adanya batu empedu, endoscopic retrograde cholangiopancreatography (ERCP) dilakukan untuk mencari dan mengatasi kemungkinan adanya mikrolitiasis. Hasil ERCP menunjukkan adanya temuan mikrolitiasis multiple sehingga segera dilakukan evakuasi. Hasil luaran klinis pasca ERCP menjadi lebih baik. Dapat disimpulkan bahwa salah satu modalitas terbaik untuk mengevaluasi mikrolitiasis pada pankreatitis akut berulang dengan kecurigaan batu empedu adalah dengan menggunakan ERCP.

**Kata kunci:** pankreatitis akut berulang, mikrolitiasis, Endoscopic retrograde cholangiopancreatography (ERCP).

## INTRODUCTION

Acute pancreatitis is a reversible inflammatory process of the pancreas. It may occur as an isolated attack or may be recurrent.<sup>1</sup> Acute recurrent pancreatitis (ARP) is a potentially life-threatening condition that requires a combination of both medical and interventional skills to diagnose, determine the etiology, and treat the condition. Recurrences occur in 25-30% of all acute pancreatitis cases.<sup>2,3</sup> Mild acute pancreatitis has a very low mortality rate (less than 1 percent), whereas severe acute pancreatitis account 10 to 30 percent depends on the presence of sterile or infective necrosis. In the United States, up to 210,000 patients per year are admitted to hospital for acute pancreatitis.<sup>4</sup>

Recurrent acute pancreatitis (RAP) has a variety of causes and range in severity, from mild to severely life threatening. There are several factors to cause a recurrent episode of acute pancreatitis. Among the causes are choledocholithiasis and alcohol consumption, account for more than 70% of all cases. Another cause of RAP are biliary microlithiasis, pancreas divisum, anomalous pancreatobiliary union, and duodenal diverticulum.<sup>3,5</sup>

Endoscopic retrograde cholangiopancreatography (ERCP) is a valuable intervention for patients suspected bile duct stones, bile duct trauma resulting in bile leaks or strictures, and benign or malignant obstruction of the bile duct. New developments in imaging modalities such as endoscopic ultrasonography and magnetic resonance cholangiopancreatography increase the options available for physicians to determine the cause of pancreatitis and assessing its complications.<sup>6</sup> This case report will report how to choose radiologic imaging modalities to diagnose the etiology of RAP.

## CASE ILLUSTRATION

A 52 year –old female had two episodes of RAP by clinical and biochemistry examination. The patient comes with epigastric pain, nausea, and vomiting as chief complaint since three days before hospital admission. She denied any history of trauma, malignancy, autoimmune disorder, jaundice, routine medication consumption, and alcohol abuse. Vital sign was normal and physical examination shows epigastric tenderness without guarding and rigidity. Bowel sound auscultation are normal. The laboratory examination result showed leukocytosis ( $12 \times 10^3$  cells/mm<sup>3</sup>), elevated amylase and lipase (1414 U/L and 517 U/L), elevated serum transaminase: aspartate aminotransferase (AST) 138 U/L and alanine transaminase (ALT) 115 U/L, elevated

serum lactate dehydrogenase serum (739 U/L), and hypoalbuminemia (2.81 g/dL).

Since the most common cause of RAP are gallstones, we decide to use radiologic imaging for evaluation. Ultrasonography showed a fatty liver without dilated duct. Abdominal computed tomography (CT) scan was considered normal (Figure 1 and 2).

The gallstone was not found in the laboratory, USG, and CT scan examination. However, we still suspected that gallstone is the etiology, so we decide to undergo ERCP compare to MRCP procedure. None of ERCP and MRCP examination were more superior, but ERCP gives a better therapy effect than MRCP in evacuating the stones. The result of ERCP showed a multiple choledocholithiasis and chronic cholecystitis. The multiple choledocholithiasis evacuated and the clinical outcome was improving.

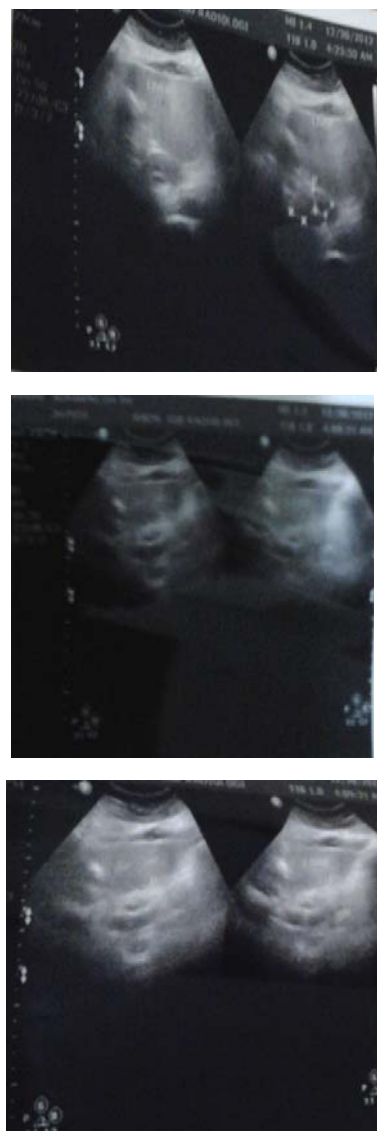

Figure 1. Ultrasonography showed fatty liver with no dilated duct

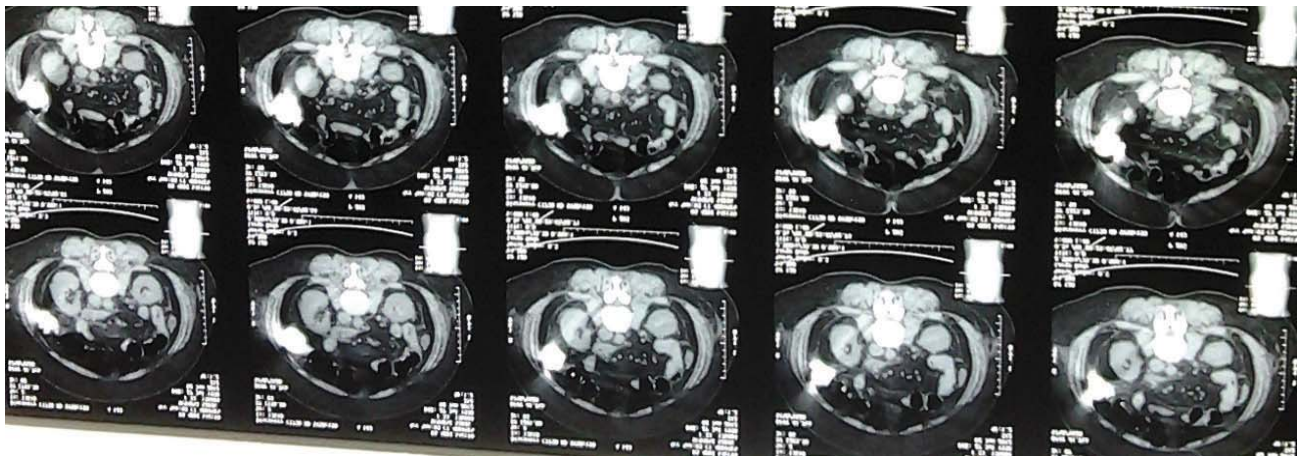


Figure 2. CT scan abdomen found no abnormalities

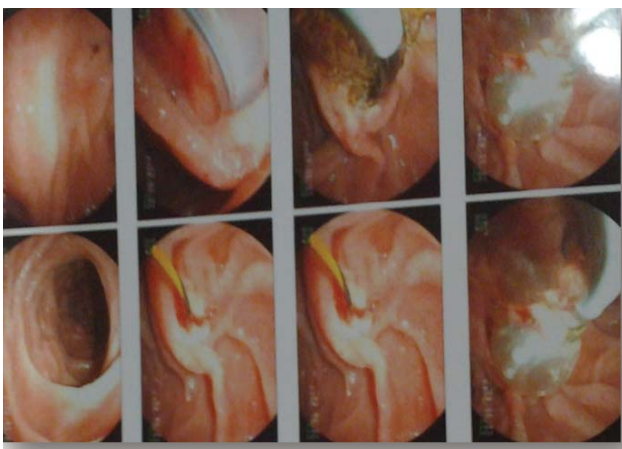


Figure 3. ERCP showed multiple choledocholithiasis and chronic cholecystitis

Based on the finding in Figure 3, we formulated that the problems were recurrent acute pancreatitis, multiple choledocholithiasis, chronic cholecystitis, fatty liver, hypoalbuminemia, and serum transaminase elevation. In the case of RAP with suspected gallstone etiology and difficult to evaluate with ultrasound and abdominal CT, ERCP could be the best modalities not only to diagnose, but also to treat microlithiasis.

## DISCUSSION

Acute pancreatitis is a condition characterized by inflammation of pancreatic tissue in the absence of any morphological changes on imaging studies. In the United States, there are 210,000 admissions for acute pancreatitis case each year. Among 10–35% of acute pancreatitis cases have recurrent episodes.<sup>1,2,3</sup>

The diagnosis of acute pancreatitis requires two of three of the following features: 1) abdominal pain consistent with the disease, 2) serum amylase and/or lipase  $\geq 3$  times the upper limit of normal range, and

3) characteristic findings on CT scan.<sup>4,7</sup> In this case, a 52 years old female came with chief complaint of epigastric pain, nausea, and vomiting for three days before admission. From the physical examination, patient were overweight (BMI = 28) and there was abdominal pain in the epigastric region during palpation. The diagnosis of this patient was made based on two features: epigastric pain and elevated of serum amylase lipase greater than three times (amylase = 1,414 U/L and lipase 517 U/L). Acute pancreatitis risk factor of this patient is overweight. In the case with RAP, we must be looking for several etiology. From the literature, there were multiple causes of recurrent acute pancreatitis, one of them is gallstone.<sup>4,3,2</sup>

The modalities generally used to evaluate the etiology of RAP is radiologic imaging. In recent years, the role of imaging modalities has greatly expanded. Traditional radiologic imaging modalities are plain film radiography, abdominal ultrasonography, CT scans, and endoscopic retrograde cholangiopancreatography (ERCP) while newer options include endoscopic ultrasonography and magnetic resonance cholangiopancreatography (MRCP). These modalities were used to confirm or exclude the clinical diagnosis, establish the etiology, assess severity, detect complications, and provide guidance for therapy.<sup>1,2,3,7</sup>

The role of initial RAP etiological evaluation was began first (level 1) with liver function tests, fasting serum calcium and lipid profile, CA19-9, and non-invasive imaging (ultrasound and/or contrast-enhanced CT abdomen). Patients who remained undiagnosed after level 1 investigations were subjected to level 2 evaluations. The patient underwent to invasive imaging techniques (MRCP, ERCP, endoscopic ultrasound (EUS)). From the level 1 examination, none of the result showed any causes of RAP, so the patient were



planned for level 2 examination. From the three modalities (MRCP, ERCP, EUS) two of them (EUS and MRCP) were noninvasive without any after-procedure complication.

Cholelithiasis and alcohol use are the most common causes of acute pancreatitis, account for more than 70% of all cases.<sup>3,2</sup> In this case, the patient did not consume alcohol. We suspected the underlying cause was lithiasis, of course without excluding any other possibility.

MRCP is a newer, non-invasive technique that has been referred as the pancreatogram. Unlike ERCP, MRCP does not have interventional capability for stone extraction, stent insertion, or biopsy.<sup>1,6</sup> Since ERCP is an invasive technique, the risk of induced acute pancreatitis, perforation, and infection were higher. MRCP was highly sensitive and specific in the evaluation of the common bile duct and can avoid to perform pure diagnostic like ERCP. In contrast to this study MRCP cannot diagnosis microlithiasis (smaller than 4 mm) or sludge as an etiology of RAP.<sup>6</sup> EUS is a noninvasive technique without any interventional functionality like ERCP.<sup>1,4,5,6,8,9,10,11</sup>

Because we suspected the causes of RAP in this case was a microlithiasis and only ERCP that could do an intervention to extract the stone, therefore we decide to perform ERCP in this patient. Through ERCP, we found the multiple microlithiasis in the common bile duct and finally extracted. The patient then referred to a digestive surgeon cholecystectomy procedure.

## CONCLUSION

A 52 years old female patient with recurrent acute pancreatitis has suspect a gallstone or microlithiasis as the etiology of RAP. Patient also in overweight and fatty liver condition. ERCP could be the best modalities to evaluate and treat multiple microlithiasis as an etiology of RAP.

## REFERENCES

1. Carroll JK, Herrick B, Gipson T. Acute pancreatitis: diagnosis, prognosis, and treatment. *Am Fam Physician* 2007;75:1513-20.
2. Mohammad Al Haddad, Wallace, MB. Diagnostic approach to patients with acute idiopathic and recurrent pancreatitis, what should be done?. *World J Gastroenterol* 2008;14:1007-10.
3. Sajith KG, Chacko A, Dutta AK. Recurrent acute pancreatitis: clinical profile and an approach to diagnosis. *Dig Dis Sci* 2010;55:3610-6.
4. Banks PA. Practice guidelines in acute pancreatitis. *Am J Gastroenterol* 2006;101:2379-400.
5. Sica GT, Braver J, Cooney MJ, Miller FH, Chai JL, Adams DF. Comparison of endoscopic retrograde

cholangiopancreatography with MR cholangiopancreatography in patients with pancreatitis. *Radiology* 1999;210:605-10.

6. Czako L, Takacs T, Morvay Z, Csernay L, Lonovics J. Diagnostic role of secretin-enhanced MRCP in patients with unsuccessful ERCP. *World J Gastroenterol* 2004;10:3034-8.
7. Sai JK, Suyama M, Kubokawa Y, Watanabe S. Diagnosis of mild chronic pancreatitis (Cambridge classification): Comparative study using secretin injection-magnetic resonance cholangiopancreatography and endoscopic retrograde pancreatography. *World J Gastroenterol* 2008;14:1218-21.
8. Mariani A, Arcidiacono PG, Curioni S, Giussani A, Testoni PA. Diagnostic yield of ERCP and secretin-enhanced MRCP and EUS in patients with acute recurrent pancreatitis of unknown aetiology. *Dig Liv Dis* 2009;41:753-8.
9. Kinney TP, Lai R, Freeman ML. Endoscopic approach to acute pancreatitis. *Rev Gastroenterol Dis* 2006;6:119-35.
10. Karen RC, Malcolm SB. Role of endoscopic retrograde cholangiopancreatography in acute pancreatitis. *World J Gastroenterol* 2007;13:6314-20.
11. Scaffidi MD, Luigiano C, Consolo P, Pellicano R, Giacobbe G, Gaeta M, et al. Magnetic resonance cholangiopancreatography versus endoscopic retrograde cholangiopancreatography in the diagnosis of common bile duct stones: a perspective comparative study. *Minerva Med* 2009;100:341-8.

---

*Correspondence:*

*Ari Fahrial Syam*

*Division of Gastroenterology*

*Department of Internal Medicine*

*Dr. Cipto Mangunkusumo General National Hospital*

*Jl. Diponegoro No.71 Jakarta Indonesia*

*Phone: +62-21-3153957 Facsimile: +62-21-3142454*

*E-mail: ari\_syam@hotmail.com*

---